# Tumor detection and identification by using Real-Time Virtual Sonography before local regional ablation

Cheng-Pin Wu, Chih-Lin Lin, Tsung-Jung Lin, Pu Wang, Wen-Chieh Wu, Yung-i Kuo, Hsi-Chang Lee, Kuan-Yang Chen, Li-Ying Liao
Departments of Gastroenterology, Taipei City Hospital, Jen-Ai branch, Taipei, Taiwan, ROC.

## Background

Most of the local regional ablation for liver tumor is performed under ultrasound guidance. However, there is sometimes difficulty in detecting the cancer lesion or in recognizing the cancer lesion among multiple liver nodules under ultrasonography. Real-time Virtual Sonography (RVS) synchronizes conventional ultrasound with a CT or MRI images. It has been widely used for the guidance of local regional therapy such as RFA. However, it is even better if the cancer lesion could be identified or recognized under ultrasonography before local regional ablation. Following up is easier if the small lesions detected in MRI could be recognized under ultrasonography. The usefulness of RVS to detect the previously undetected tumor or to identify a cancer lesion among others has not been assessed. The aim of this study is to evaluate the usefulness of RVS in recognizing cancer lesion before the treatment of HCC.

## Methods

A total of 44 patients with 61 tumors (45 HCCs and 16 indeterminate arterial-enhancing nodules; mean diameter: 1.13+/-0.41cm) with a pre-treatment RVS performed during September 2015 and March 2017 were included. Most of them were HCC recurrence cases. The 61 tumors were divided into three groups according to the purpose of the RVS exam. **(Figure 1.)**

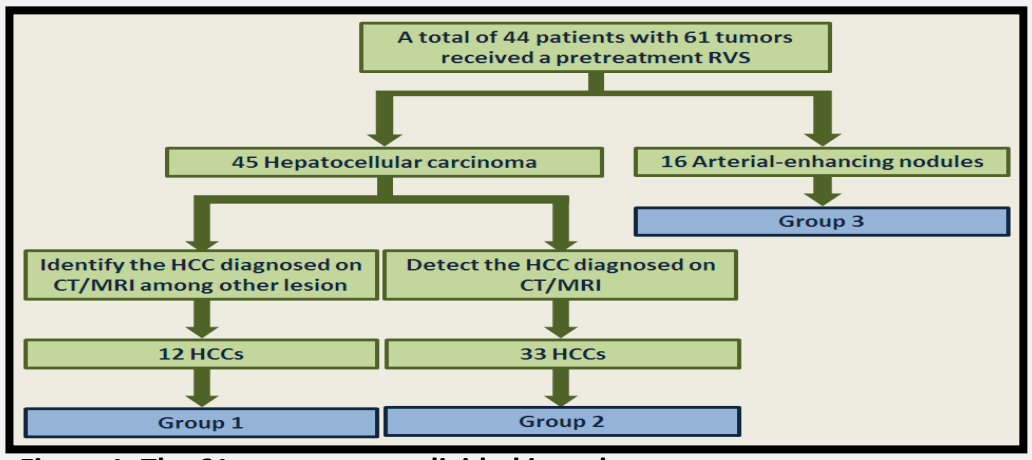


**Figure 1. The 61 tumors were divided into three groups.**

## Results

1. The demographic and clinical characteristics of patients receiving RVS are shown in **Table 1**. The total case number was exceeding 44 because some patients had tumors belong to different groups.
2. The rate of the tumor visible under RVS, the tumor size and the subsequent treatment were shown in **Table 2**.
3. Among the 12 HCC in group 1, eight (75%) tumors could be identified by RVS study.
4. 24 of the 33 HCC tumors (72.7%) in group 2 could be detected under RVS study.
5. Only 5 of the 16 (31%) indeterminate arterial-enhancing nodules were visible under RVS study. 64% of the undetectable nodules disappeared in the follow up study by multiphasic CT or MRI.

| | Group 1 | Group 2 | Group 3 |
|---|---|---|---|
| Age (Mean ± SD) | 63.14 ± 7.80 | 69.12 ± 9.25 | 66.71 ± 9.98 |
| Case number | 7 | 25 | 14 |
| Male | 4(57%) | 15(60%) | 5(36%) |
| Female | 3(43%) | 10(40%) | 9(64%) |
| Hepatitis profile | | | |
| Positive for HBV | 7(100%) | 15(60%) | 9(64%) |
| Positive for HCV | 0(0%) | 9(36%) | 3(21%) |
| Child-Pugh class | | | |
| A | 6(86%) | 23(92%) | 14(100%) |
| B | 1(14%) | 2(8%) | 0(0%) |

**Table 1. Demographic and clinical characteristics of patients receiving RVS**

| | Group 1 | Group 2 | Group 3 |
|---|---|---|---|
| Tumor number | 12 | 33 | 16 |
| Mean tumor size | 1.03±0.23cm | 1.16 ± 0.46cm | 1.08 ± 0.38cm |
| Detectable by RVS | | | |
| Yes | 8(75%) | 24(72.7%) | 5(31.2%) |
| No | 4(25%) | 9(26.3%) | 11(68.8%) |
| Treatment | | | |
| PEI | 4 | 11 | 0 |
| RFA | 1 | 6 | 0 |
| Operation | 0 | 3 | 0 |
| Other | 7 (5 TACE + 2 no treatment) | 13 (3 TACE + 10 follow-up) | 16 |

**Table 2. Mean sizes and different treatment of tumors in each groups**

## Conclusions

1. RVS is useful in identifying the small tumor lesions of HCC among multiple lesions and in detecting the very vague lesions and tiny neglected lesions. Over 70% tumor lesions could be well identified before local regional treatment.
2. In contrast, only 30% of the small indeterminate nodules showing arterial-enhancing pattern but no typical washout pattern of HCC could be detected under RVS study. Over 60% of the RVS undetectable nodules became invisible in the follow up multiphasic CT or MRI studies, suggesting flow artifact. Therefore, RVS is also useful in differentiating tumor from artifact.
3. It is more difficult to detect the viable part inside a treated tumor lesion.